

# Methods for segmentation of spinal cord and esophagus in radiotherapy planning computed tomography

João Otávio Bandeira Diniz

Universidade Federal do Maranhão (UFMA)

Caixa Postal 65.085-580, São Luís — MA — Brasil

Email: joao.bandeira@ifma.edu.br

Aristófanés Corrêa Silva

Universidade Federal do Maranhão (UFMA)

Caixa Postal 65.085-580, São Luís — MA — Brasil

Email: ari@nca.ufma.br

Anselmo Cardoso de Paiva

Universidade Federal do Maranhão (UFMA)

Caixa Postal 65.085-580, São Luís — MA — Brasil

Email: paiva@nca.ufma.br

**Abstract**—Organs at Risk (OARs) are healthy tissues around cancer that must be preserved in radiotherapy (RT). The spinal cord and esophagus are crucial OARs. In this work, we proposed methods for the segmentation of these OARs from the CT using image processing techniques and deep convolutional neural network (CNN). For spinal cord segmentation, two methods are proposed, the first using techniques such as template matching, superpixel, and CNN. The second method, use adaptive template matching and CNN. In the esophagus segmentation, we proposed a method composed of registration techniques, atlas, pre-processing, U-Net, and post-processing. The methods were applied to 36 planning CT images provided by The Cancer Imaging Archive. The first method for spinal cord segmentation obtained 78.20% Dice. The second method for spinal cord segmentation obtained 81.69% Dice. The esophagus segmentation method obtained an accuracy of 82.15% Dice.

## I. INTRODUCTION

Radiotherapy (RT) is an effective and commonly used option in cancer treatment, especially when surgery and chemotherapy present an extremely high risk to the patient. It plays a key role in the treatment of more than 50% of cancer cases, and 40% of patients cured of cancer have RT as part of their treatment [1].

Due to its advances, radiotherapy can be used in several tumor sites and can be used before or after definitive surgery [1]. The RT treatment process is multidisciplinary, involving clinical oncologists, physicists, physicians, and therapeutic radiologists [1]. The RT process consists of some steps, one of the most important steps being planning, where first the patient is submitted to tomography and in it the delineation of the tumors, and healthy tissues are made.

Cancer treatments are toxic, which is no different from RT [2]. In short, ionizing rays are sent to target tissue to eradicate or control cancer progression. However, this radiation release needs to be well planned. Since, around this target tissue, there are tissues/organs sensitive to radiation. Excess

radiation on healthy organs can cause undesirable or even irreversible effects [1]. These healthy tissues/organs are known as Organs at Risk (OARs).

In radiotherapy, one of the goal OARs to be protected is the spinal cord. Excessive radiation to this organ can cause several problems, such as paraplegia or quadriplegia, depending on the extent to which it has been irradiated. In turn, the esophagus is the most critical organ, the dose recommended in the literature is around 50 to 60 cGy [3].

Research has invested substantially in developing systems based on imaging techniques to delineate tumor and OARs with greater precision, mainly to help specialists circumvent the toxicity effects of radiotherapy and reduce adverse effects on the human body. [1]. These combined techniques implied to development of computer-assisted detection (CAD). Specifically, some of these are focused on providing three-dimensional images of internal organs to support RT planning and pretreatment [4].

This task takes time from the experts and involves a large team of professionals. It is also exhaustive and error-prone, especially in organs such as the spinal cord and esophagus, which span multiple CT slices and require precise segmentation. Thus, this work complements these systems, aiming at automatic spinal cord segmentation and esophagus segmentation in CT planning.

Thus, the main objective of the proposed work is to develop computational methods based on image processing and machine learning techniques for spinal cord and esophagus segmentation in CT planning for RT.

By proposing fully automatic and innovative methods, the method has several contributions, including:

- 1) Advances in the *template matching* technique, making it adaptable to each slice of a CT image;
- 2) Use of the IMSLIC superpixel technique for the first time in medical imaging and with promising results;

- 3) Proposition of a CNN architecture capable of classifying these superpixels in the spinal cord;
- 4) Esophagus enhancement using image processing techniques, since its limits are not well defined on CT;
- 5) Proposition of a CNN architecture capable of effectively segmenting the esophagus;
- 6) Building two robust methods for automatically detecting the spinal cord and other capable of highlighting and detecting the esophagus on planning CT.

The following sections presented the proposed methods and the results achieved. Finally, we present the conclusion and the scientific productions done during the thesis.

## II. MATERIALS E METHODS

During the Ph.D., two spinal cord segmentation methods and one method for esophagus segmentation were proposed, both in RT planning CT. The methods were created and validated using the database called *AAPM Thoracic Auto-segmentation* [5]. The main objective of this challenge is to encourage participants to create algorithms for the segmentation of organs at risk (OARs) in planning CT of patients who will undergo radiotherapy treatment.

The database consists of 36 CTs divided equally into three institutes (12 patients per institute). The acquisition is done in a diversified way with several acquisition protocols, which makes the creation of robust and generalize methods more challenging. The methods are presented below.

### A. First spinal cord segmentation method

This method is basically divided into four steps. These steps are described in Figure 1.

Briefly, the first step is the images acquisition that refers to the database described above. The second step is the initial segmentation, this step is done to reduce the region of interest of the volumes, isolating the spinal cord region, for this, a technique of *template matching*. An initial template is given, and it is adaptable to all patient slices. As a result of this step, all patients will have their volumes reduced, resulting in a VOI.

With segmented VOIs, candidate segmentation begins, regions are grouped using the *superpixel* IMSLIC technique. The superpixel algorithm groups pixels based on intensity; this is of extreme advantage when you know that the intensity values of the spinal cord differ from other regions around it.

The fourth step, classification of candidates, regions grouped by IMSLIC will be used for training and classification in a convolutional neural network (CNN). As a result, we have the regions of the image classified as the spinal cord. Finally, validation metrics are extracted to quantify the proposed method [6].

This method is very promising, mainly by adapting *template matching* to the use in CT, making it adaptive for each patient. The use of the IMSLIC superpixel algorithm for candidate segmentation was proposed, this was the first time that this technique was used in medical images.

### B. Second spinal cord segmentation method

For the second method of spinal cord segmentation in planning CT, a method divided into three steps is proposed. First image acquisition, we used the same one described above.

Second, initial segmentation, where a subvolume is generated per patient containing only the spinal cord region and surrounding objects also using *template matching*. In this second method, we reduce the template search region, reducing its computational cost and improving results, since it is no longer necessary to search for matches in the entire slice.

Finally, in the segmentation step, the spinal cord will be segmented using three U-Net approaches considered as state of the art in segmentation tasks. Finally, validation metrics are calculated to validate the robustness of the proposed method [7], [8]. These steps are described in Figure 2.

In this method, we made the template matching technique proposed in the first method even more robust, making its execution faster and more effective, reducing the computational time by 1/3. Furthermore, we proposed to use three state-of-the-art U-Nets in the segmentation task, which made the method even more robust and achieved better results than the first method.

### C. Esophagus segmentation method

For esophagus segmentation in planning CT, a method divided into 4 steps is proposed. First, it is the image acquisition step, the base used is the one described above. The marking of the esophagus, as well as many other works report [9], is one of the most difficult OARs to delimited.

In the second step, in the segmentation of the VOI, spatial information from an Atlas of the esophagus is used to make a three-dimensional cut in the volume. The atlas technique is one of the most used in the literature, as it takes radiological (anatomical) information to refine the segmentation.

Then, to highlight the structures of the esophagus, pre-processing is done using a bilateral filter followed by the equalization of the histogram. Few studies focus on the use of enhancement techniques to highlight the esophagus in CTs. Thus, observing the literature, it is possible to propose a set of enhancement techniques that improve the delimitation of the esophagus.

Then, in the final segmentation step, the VOI slices are presented to a U-Net with residual blocks to create a model capable of segmenting the esophagus region, and, finally, a refinement technique is applied to improve the segmentation of the esophagus [10]. Figure 3 describes the steps of this method.

This method presents a set of techniques that together produced results superior to the literature. We propose improvement techniques based on medical images using bilateral filter followed by histogram equalization, these techniques make it possible to enhance the edges of the esophagus, improving the input images of the network. We also propose the use of Atlas to reduce the scope of segmentation and, consequently, the computational load. We propose a new Res-U-Net, composed

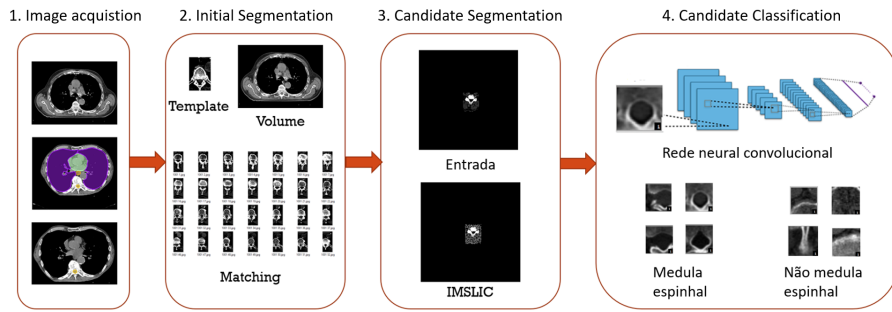


Fig. 1. Flow of the first spinal cord method.

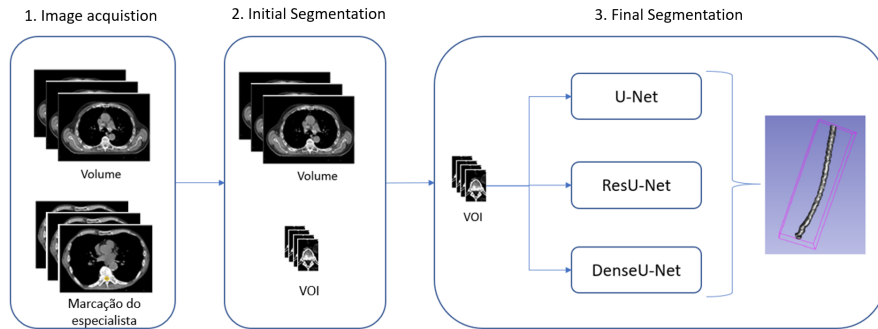


Fig. 2. Flow of the second spinal cord method.

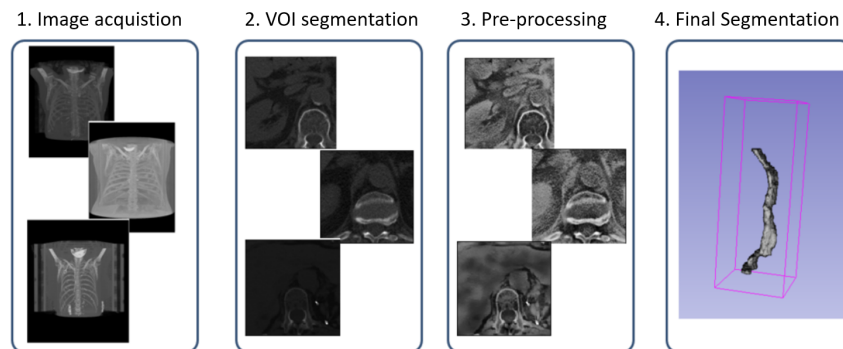


Fig. 3. Flow of the esophagus segmentation method.

of residual blocks, dropout, leakyReLU, batch normalization, this network showed promise also reaching expressive results for COVID-19 segmentation [11] and heart [12]. Furthermore, we propose a post-processing step, which sought to reduce the false positives generated.

### III. RESULTS

Results for spinal cord and esophagus segmentation are presented in this section. Also, we describe a comparison with literature and case studies of each method.

#### A. Spinal cord segmentation results

We proposed two methods for spinal cord segmentation. These resulted in four scientific papers, three published [6]–

[8] and one Under Review in *Biomedical Signal Processing and Control*.

The first method consists of four steps. Briefly, the first is image acquisition from a public database. The second is the initial segmentation, which aims to reduce the regions to be analyzed, an adaptive template matching technique is proposed. In the third step, the candidate segmentation is performed using the IMSLIC technique, a superpixel technique that was used for the first time in medical images in this work. Finally, a CNN classifies candidates into the spinal cord and no spinal cord. As a result, this method achieves 78.2% of Dice.

The second method consists of three steps. Briefly, the first

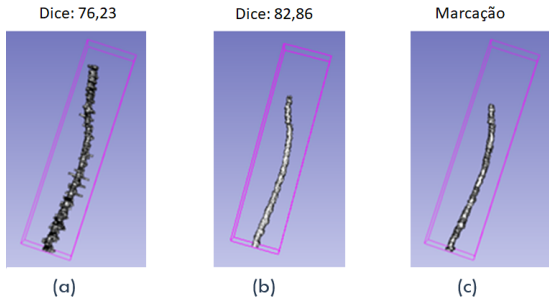


Fig. 4. Case study: (a) volume predicted by method 1, (b) predicted by method 2 and (c) specialist appointment.

is image acquisition from a public database. The second is the initial segmentation, which aims to reduce the regions to be analyzed an improvement in the adaptive template matching technique proposed in the previous method is proposed. Finally, three CNNs final segments the spinal cord. The best result of the three networks was 81.69% of Dice.

1) *Comparison with literature*: Compared to literature, the methods have their place of prominence. Table I describes some related works comparing them to the proposed methods.

TABLE I  
COMPARISON WITH RELATED WORKS.

Work	Database	Technique	Patient	Dice
Banik et al [13]	Private	Semi-automatic	13	60%
VelocityAI [14]	Private	Semi-automatic	15	70%
MIM 5.1.1 [14]	Private	Semi-automatic	15	81%
ABAS 2.0 [14]	Private	Semi-automatic	15	78%
De Lenner et al [15]	Private	Semi-automatic	17	91%
Verhaart et al [16]	Private	Semi-automatic	27	87%
Ibragimov et al [17]	AAPM Thoracic Auto-segmentation	Automatic	36	87%
Dong et al [18]	AAPM Thoracic Auto-segmentation	Automatic	35	90%
Liu et al [19]	Private	Automatic	105	82,70%
Proposed method (CNN)	AAPM Thoracic Auto-segmentation	Automatic	36	78,20%
Proposed method (ResU-Net)	AAPM Thoracic Auto-segmentation	Automatic	36	81,69%

Regarding the works described in Table I, it is noteworthy that our work presents two fully automatic methods, the first being based on *superpixels* and CNN, which in addition to better delimiting the spinal cord region spinal, does not require *a priori* knowledge. The second method features U-Net-based spinal cord segmentation. We highlighted the great difficulty in making a faithful comparison since the image databases are not the same. Some databases are different from the work presented, so it was impossible to apply the proposed method. However, it is noteworthy that the proposed methods had the largest number of patients to validate, which can also be highlighted as robustness. Also, compared to validation metrics, our approaches have a prominent place. Thus, we demonstrated the feasibility of using the methods proposed for the spinal cord segmentation task.

2) *Case studies*: We now present a comparison between the methods through case studies. Figure 4 illustrates the result of the two methods applied to a patient from the test database.

The results are promising. The first method, because it is based on *superpixels*, has more irregular edges, while the second one, based on U-Net, presents greater smoothness on the edges, and results much closer to specialist marking.

## B. Esophagus segmentation results

A method for esophagus segmentation has been proposed. This resulted in a scientific paper [10].

First is the image acquisition step, using a public database. In the second step, in the segmentation of the volume of interest (VOI), spatial information from an atlas of the esophagus is used to make a three-dimensional cut in the volume. Then, we make pre-processing using a bilateral filter followed by the equalization of the histogram. Then, in the final segmentation step, the VOI slices are presented to CNN to create a model capable of segmenting the esophagus region, and, finally, a refinement technique is applied to improve the segmentation of the esophagus. As a result, the method achieved 82.15% of Dice, the best in the literature so far.

1) *Comparison with literature*: Compared to literature, the method has its prominent place. Table I describes some related works comparing them to the proposed method for esophagus segmentation.

TABLE II  
COMPARISON WITH RELATED WORKS.

Work	Database	Patient	Dice
Feulnet et al [20]	Private	144	74%
Grosgeorge et al [21]	Private	6	61%
Larsson et al [22]	MICCAI 2015	30	66,2%
Trullo et al [23]	MICCAI 2015	30	66%
Trullo et al [24]	MICCAI 2015	30	72%
Fechter et al [9]	MICCAI 2015	50	76%
Dong et al [18]	AAPM Thoracic Auto-segmentation	35	75%
Chen et al [25]	Private	15	79%
Feng et al [26]	AAPM Thoracic Auto-segmentation	36	72%
Lou et al [27]	Private	17	86,80%
Proposed method(ResU-Net)	AAPM Thoracic Auto-segmentation	36	82,15%

We observed that the literature presents several recent works for esophagus segmentation. As it is not a trivial task, not even for specialist physicians, the highest value found in the literature so far is 76% of Dice. All works show the need for a reduction in the scope of patient volume for segmentation. This information was valuable when building our method, where we used recording techniques and atlases to segment the VOI.

It was also possible to observe that none of these works improve the image. So a crucial step in our method was to find enhancement techniques that could improve the visualization of the esophagus. Another important point is the fact that after the classification of the network, as it is an OAR that is similar in texture to the other organs and tissues, a refinement step was necessary, which generated very promising results.

Thus, it is noteworthy that our work presented an automatic method for segmenting the esophagus. This consists of techniques observed in the literature and techniques developed by us to ensure better results. Although the databases used are different from the ones used in our work, it manages to surpass almost all the works presented so far in the literature. Thus, the feasibility of using the method proposed in the esophagus segmentation task is demonstrated.

2) *Case studies*: We now present a comparison between the methods through case studies. The result of applying the method can be seen in Figure 5.

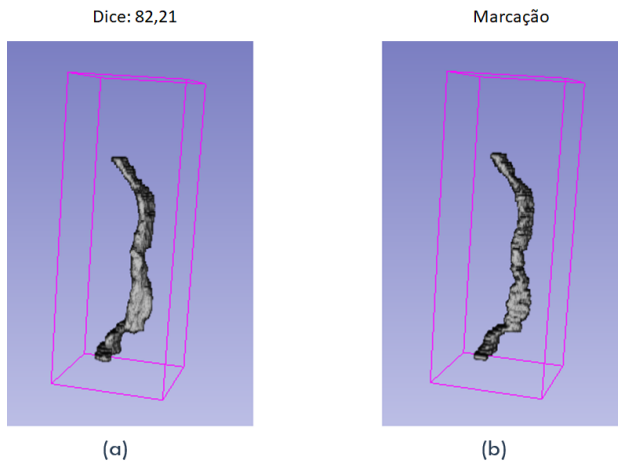


Fig. 5. Case study: (a) volume predicted by the method and (b) volume of specialist marking.

The results are promising. Observing the figure, we visualize that the model was very robust in segmenting the esophagus, approaching the specialist's marking.

#### IV. DISCUSSION

Discussions for spinal cord and esophagus methods are shown in this section.

##### A. Discussion of spinal cord methods

Protecting the spinal cord as an organ at risk is a fundamental task in planning radiotherapy. The automatic segmentation of the spinal cord by the two methods proved to be promising, and we highlight some advances:

- Two fully automatic methods developed on a public and diversified basis, with good hit rates;
- Proposition of techniques for initial region segmentation using adaptive template matching proposed in this work
- First time use of IMSLIC on medical imaging in the first method;
- Classification using a CNN of these superpixels in the first method allowed the abstraction of the extraction, selection, and classification of features steps;
- In method 2, we used three U-Net segmentation networks considered to be state of the art in the problem of medical images;
- With these networks, the results of the first method were improved and achieved even more promising results.

Some limitations can be highlighted:

- By using CNNs, there is a need to search for better parameters, this step can be optimized by an optimizer;
- Both methods use adaptive template matching, which despite being quite robust, require a 'kickstart' from an initial template.

##### B. Discussion of esophagus method

Developing a method capable of circumventing all the adversities of the esophagus and achieving a success rate is still

a challenge. The proposed method for esophagus segmentation proved to be quite robust and presented several advantages:

- The VOI segmentation step proved to be pertinent since the esophagus represents a very small portion of the planning CT exam;
- The pre-processing step proved to be crucial to achieving better results, the method achieved an improvement of more than 20% of Dice when using the sequence of two pre-processes;
- The refinement steps further improved the results of the segmentation step;
- The set of steps brought promising results, showing the best result in the literature so far;
- A robust method used in large medical centers can help the specialist to save more lives and avoid errors due to fatigue.

We highlight some negative points:

- The CNN network has many parameters, optimizing your selection can improve the result;
- The method was tested only on an image base, which despite being quite diversified, does not encompass all types of existing tomographs.

Thus, this doctoral thesis directly presented three computational methods to assist physicians in cancer treatment through automatic segmentation of the spinal cord and esophagus. Related to the method, we developed five scientific papers. During the doctorate, it was possible to develop more than 35 scientific papers.

#### V. CONCLUSION

For both spinal cord segmentation methods, we used the *template matching* technique to make an initial segmentation of the spinal cord region, reducing the scope for the classification algorithms. In the first method, this technique helped both the other steps and the computational cost of not perform the IMSLIC on the entire volume. In the second method, the *template matching* technique helped to reduce the input images of U-Nets and, consequently, the computational cost.

To improve both methods, we suggested searching for algorithms that can automate the hyperparameters, both CNN and U-Nets. Thus, being able to present better results. Also, testing in other databases can further validate the methods.

For the esophagus segmentation, we associate the most used techniques in the literature and propose improvements to the existing ones to generate promising results. The VOI segmentation step was crucial for the initial results, so it was possible to reduce the scope of the volume and, in this way, provide improvements in the results. The pre-processing step proved to be essential, as it was possible to highlight the edges of the esophagus and, consequently, transmit valuable information to ResU-Net.

However, as already mentioned, the training stage has a segmentation network composed of numerous parameters and layers these hyperparameters are adjusted in the validation phase, which takes time. Automating this step could produce

better results. There is a difference between the three institutes used, a way to standardize the texture could also improve the results.

## VI. SCIENTIFIC PRODUCTION

During the development of the methods, it was possible to produce a series of scientific articles. These were published in all spheres, whether in national or international congresses or national or international journals.

Directly related to the work, five papers were published, described in following:

- A deep learning method with residual blocks for automatic spinal cord segmentation in planning CT – Biomedical Signal Processing and Control – Qualis A1 – JCR 3.88%;
- Spinal cord detection in planning ct for radiotherapy through adaptive template matching, imslc and convolutional neural network – Computer Methods and Programs in Biomedicine – Qualis A1 – JCR 3.434%
- Spinal cord segmentation as OAR in planning CT for radiotherapy using histogram matching, template matching, and U-Net – Revista de Sistemas e Computação – Qualis B5
- Automatic spinal cord segmentation as organ at risk in planning CT using adaptive template matching and U-Net – Anais da Escola Regional de Computação Aplicada à Saúde – Qualis B5
- Esophagus segmentation from planning CT images using an atlas-based deep learning approach – Computer Methods and Programs in Biomedicine – Qualis A1 – JCR 3.434%

Furthermore, it was possible to publish other works using the knowledge acquired during the four years of doctorate and in partnership with other researchers, resulting in 1 book chapter, 14 journals, and 21 conferences. Moreover, there are four journals and two conferences under review.

Finally, in recognition of the scientific contribution of the work entitled *Detection of mass regions in mammograms by bilateral analysis adapted to breast density using similarity indexes and convolutional neural networks* published in the journal *Computer Methods and Programs in Biomedicine* [28], this was considered by the *International Medical Informatics Association Yearbook editorial board* one of the four most relevant works in the scientific community (in a worldwide selection of 1,459 methods published in 2018) in the field of *Sensor, Signal and Imaging Informatics* [29].

## REFERENCES

- [1] E. Evans and J. Staffurth, "Principles of cancer treatment by radiotherapy," *Surgery-Oxford International Edition*, vol. 36, no. 3, pp. 111–116, 2018.
- [2] M. Button and J. Staffurth, "Clinical application of image-guided radiotherapy in bladder and prostate cancer," *Clinical Oncology*, vol. 22, no. 8, pp. 698–706, 2010.
- [3] B. N. Ruppert, J. M. Watkins, K. Shirai, A. E. Wahlquist, E. Garrett-Mayer, E. G. Aguero, C. A. Sherman, C. E. Reed, and A. K. Sharma, "Cisplatin/irinotecan versus carboplatin/paclitaxel as definitive chemoradiotherapy for locoregionally advanced esophageal cancer," *American journal of clinical oncology*, vol. 33, no. 4, pp. 346–352, 2010.
- [4] M. Chen, A. Carass, J. Oh, G. Nair, D. L. Pham, D. S. Reich, and J. L. Prince, "Automatic magnetic resonance spinal cord segmentation with topology constraints for variable fields of view," *Neuroimage*, vol. 83, pp. 1051–1062, 2013.
- [5] J. Yang, H. Veeraraghavan, S. G. Armato III, K. Farahani, J. S. Kirby, J. Kalpathy-Kramer, W. van Elmpt, A. Dekker, X. Han, X. Feng *et al.*, "Autosegmentation for thoracic radiation treatment planning: a grand challenge at aapm 2017," *Medical physics*, vol. 45, no. 10, pp. 4568–4581, 2018.
- [6] J. O. B. Diniz, P. H. B. Diniz, T. L. A. Valente, A. C. Silva, and A. C. Paiva, "Spinal cord detection in planning ct for radiotherapy through adaptive template matching, imslc and convolutional neural networks," *Computer methods and programs in biomedicine*, vol. 170, pp. 53–67, 2019.
- [7] J. Diniz, J. Ferreira, P. Diniz, B. Serejo, N. Ribeiro, O. Santos, A. Silva, and A. Paiva, "Automatic spinal cord segmentation as organ at risk in planning ct using adaptive template matching and u-net," in *Anais da VII Escola Regional de Computação Aplicada à Saúde*. Porto Alegre, RS, Brasil: SBC, 2019, pp. 151–156. [Online]. Available: <https://sol.sbc.org.br/index.php/ercas/article/view/9051>
- [8] —, "Spinal cord segmentation as oar in planning ct for radiotherapy using histogram matching, template matching, and u-net," *Revista de Sistemas e Computação*, 2020.
- [9] T. Fechter, S. Adebahr, D. Baltas, I. B. Ayed, C. Desrosiers, and J. Dolz, "Esophagus segmentation in ct via 3d fully convolutional neural network and random walk," *Medical physics*, vol. 44, no. 12, pp. 6341–6352, 2017.
- [10] J. O. B. Diniz, J. L. Ferreira, P. H. B. Diniz, A. C. Silva, and A. C. de Paiva, "Esophagus segmentation from planning ct images using an atlas-based deep learning approach," *Computer Methods and Programs in Biomedicine*, vol. 197, p. 105685, 2020.
- [11] J. O. Diniz, D. B. Quintanilha, A. C. S. Neto, G. L. da Silva, J. L. Ferreira, S. M. Netto, J. D. Araújo, L. B. Da Cruz, T. F. Silva, C. M. d. S. Martins *et al.*, "Segmentation and quantification of covid-19 infections in ct using pulmonary vessels extraction and deep learning," *Multimedia Tools and Applications*, pp. 1–33, 2021.
- [12] J. Diniz, J. Ferreira, G. Silva, D. Quintanilha, A. Silva, and A. Paiva, "Segmentação de coração em tomografias computadorizadas utilizando atlas probabilístico e redes neurais convolucionais," in *Anais do XXI Simpósio Brasileiro de Computação Aplicada à Saúde*. Porto Alegre, RS, Brasil: SBC, 2021, pp. 83–94. [Online]. Available: <https://sol.sbc.org.br/index.php/sbcas/article/view/16055>
- [13] S. Banik, R. M. Rangayyan, and G. S. Boag, "Automatic segmentation of the ribs, the vertebral column, and the spinal canal in pediatric computed tomographic images," *Journal of digital imaging*, vol. 23, no. 3, pp. 301–322, 2010.
- [14] M. La Macchia, F. Fellin, M. Amichetti, M. Cianchetti, S. Gianolini, V. Paola, A. J. Lomax, and L. Widesott, "Systematic evaluation of three different commercial software solutions for automatic segmentation for adaptive therapy in head-and-neck, prostate and pleural cancer," *Radiation Oncology*, vol. 7, no. 1, p. 160, 2012.
- [15] B. De Leener, J. Cohen-Adad, and S. Kadoury, "Automatic segmentation of the spinal cord and spinal canal coupled with vertebral labeling," *IEEE transactions on medical imaging*, vol. 34, no. 8, pp. 1705–1718, 2015.
- [16] R. F. Verhaart, V. Fortunati, G. M. Verduijn, T. van Walsum, J. F. Veenland, and M. M. Paulides, "Ct-based patient modeling for head and neck hyperthermia treatment planning: Manual versus automatic normal-tissue-segmentation," *Radiotherapy and Oncology*, vol. 111, no. 1, pp. 158–163, 2014.
- [17] B. Ibragimov and L. Xing, "Segmentation of organs-at-risks in head and neck ct images using convolutional neural networks," *Medical physics*, vol. 44, no. 2, pp. 547–557, 2017.
- [18] X. Dong, Y. Lei, T. Wang, M. Thomas, L. Tang, W. J. Curran, T. Liu, and X. Yang, "Automatic multiorgan segmentation in thorax ct images using u-net-gan," *Medical physics*, vol. 46, no. 5, pp. 2157–2168, 2019.
- [19] Z. Liu, X. Liu, B. Xiao, S. Wang, Z. Miao, Y. Sun, and F. Zhang, "Segmentation of organs-at-risk in cervical cancer ct images with a convolutional neural network," *Physica Medica*, vol. 69, pp. 184–191, 2020.
- [20] J. Feulner, S. K. Zhou, M. Hammon, S. Seifert, M. Huber, D. Comanicu, J. Hornegger, and A. Cavallaro, "A probabilistic model for automatic segmentation of the esophagus in 3-d ct scans," *IEEE transactions on medical imaging*, vol. 30, no. 6, pp. 1252–1264, 2011.

- [21] D. Grosgeorge, C. Petitjean, B. Dubray, and S. Ruan, "Esophagus segmentation from 3d ct data using skeleton prior-based graph cut," *Computational and mathematical methods in medicine*, vol. 2013, 2013.
- [22] M. Larsson, Y. Zhang, and F. Kahl, "Robust abdominal organ segmentation using regional convolutional neural networks," in *Scandinavian Conference on Image Analysis*. Springer, 2017, pp. 41–52.
- [23] R. Trullo, C. Petitjean, S. Ruan, B. Dubray, D. Nie, and D. Shen, "Segmentation of organs at risk in thoracic ct images using a sharp-mask architecture and conditional random fields," in *2017 IEEE 14th International Symposium on Biomedical Imaging (ISBI 2017)*. IEEE, 2017, pp. 1003–1006.
- [24] R. Trullo, C. Petitjean, D. Nie, D. Shen, and S. Ruan, "Fully automated esophagus segmentation with a hierarchical deep learning approach," in *2017 IEEE International Conference on Signal and Image Processing Applications (ICSIPA)*. IEEE, 2017, pp. 503–506.
- [25] S. Chen, H. Yang, J. Fu, W. Mei, S. Ren, Y. Liu, Z. Zhu, L. Liu, H. Li, and H. Chen, "U-net plus: Deep semantic segmentation for esophagus and esophageal cancer in computed tomography images," *IEEE Access*, vol. 7, pp. 82 867–82 877, 2019.
- [26] X. Feng, K. Qing, N. J. Tustison, C. H. Meyer, and Q. Chen, "Deep convolutional neural network for segmentation of thoracic organs-at-risk using cropped 3d images," *Medical physics*, vol. 46, no. 5, pp. 2169–2180, 2019.
- [27] X. Lou, Y. Zhu, K. Punithakumar, L. H. Le, and B. Li, "Esophagus segmentation in computed tomography images using a u-net neural network with a semiautomatic labeling method," *IEEE Access*, vol. 8, pp. 202 459–202 468, 2020.
- [28] J. O. B. Diniz, P. H. B. Diniz, T. L. A. Valente, A. C. Silva, A. C. de Paiva, and M. Gattass, "Detection of mass regions in mammograms by bilateral analysis adapted to breast density using similarity indexes and convolutional neural networks," *Computer Methods and Programs in Biomedicine*, vol. 156, pp. 191–207, 2018.
- [29] W. Hsu, C. Baumgartner, T. Deserno *et al.*, "Advancing artificial intelligence in sensors, signals, and imaging informatics," *Yearbook of medical informatics*, vol. 28, no. 01, pp. 115–117, 2019.